



Recurrent urinary retention secondary to a posterior uterine leiomyoma

Retención urinaria recurrente secundaria a leiomioma uterino de cara posterior

Yoanna Ramirez-Fernandez ¹ <https://orcid.org/0000-0002-6343-3781>

Karel Borroto-Martinez ^{1*} <https://orcid.org/0000-0002-3183-1312>

¹ Clinical Research Center. Havana, Cuba.

*Corresponding author. Email: karelborroto@infomed.sld.cu

ABSTRACT

Introduction: Uterine leiomyomas are benign smooth muscle tumors and are the most common pelvic tumors among women of reproductive age. Its maximum incidence peak is in the fourth and fifth decades of life.

Objective: To describe a case of recurrent urinary retention secondary to a posterior uterine leiomyoma.

Clinical case: 42-year-old nulliparous patient with a history of recurrent urinary retention on three occasions in the last 4 months. On physical examination, the

patient presented with a painful tumor measuring 8 cm in diameter in the hypogastrium. The tomography showed that it compressed and displaced the rectosigmoid and the bladder, with increased central and peripheral vascularization that showed neoformation. A total abdominal hysterectomy was performed and it was concluded as an intramural epithelioid leiomyoma.

Conclusion: This case emphasizes the importance of clinical and diagnostic correlation in those patients with recurrent

<http://revcimeq.sld.cu/index.php/imq>
revinmedquir@infomed.sld.cu

Under Creative Commons license





urinary retention; in addition to exposing the rarity of a posterior leiomyoma that presented with urinary symptoms and with imaging signs suspicious of malignancy.

RESUMEN

Introducción: Los leiomiomas uterinos son tumores benignos del músculo liso y constituyen los tumores pélvicos más comunes entre las mujeres en edad reproductiva. Su pico máximo de incidencia es en la cuarta y quinta décadas de la vida.

Objetivo: Describir un caso de retención urinaria recurrente secundaria a un leiomioma uterino de cara posterior.

Caso clínico: Paciente de 42 años de edad, nulípara, con historia de retención urinaria recurrente en tres ocasiones en los últimos 4 meses. Presentaba al examen físico un tumor doloroso y de 8 cm de diámetro en hipogastrio. En la tomografía se observó que

Key Words: epithelioid leiomyoma; urinary retention; neoplasia.

comprimía y desplazaba al recto-sigmoidees y a la vejiga, con vascularización aumentada, central y periférica que impresionaba neoformación. Se realizó histerectomía total abdominal y se concluyó como leiomioma epiteliode intramural.

Conclusión: Este caso recalca la importancia de la correlación clínica y diagnóstica en aquellas pacientes con retención urinaria recurrente; además de exponer la rareza de un leiomioma de cara posterior que se presentó con sintomatología urinaria y con signos imagenológicos sospechosos de malignidad.

Palabras clave: leiomioma epiteliode; retención urinaria; neoplasia.

<http://revcimeq.sld.cu/index.php/img>
revinmedquir@infomed.sld.cu

Under Creative Commons license





Received: 10/04/2024

Accepted: 08/14/2024

INTRODUCTION

Uterine leiomyomas are benign smooth muscle tumors and are the most common pelvic tumors, with a prevalence of 20-40% in women of reproductive age. ⁽¹⁾ They are benign monoclonal tumors that arise from the smooth muscle cells of the myometrium; however, a rare variant has been described that cannot be defined as benign or malignant based on its clinical and histopathological findings. ⁽²⁾

The World Health Organization classifies this neoplasm as a uterine smooth muscle tumor of uncertain malignant potential (STUMP). ⁽³⁾ Up to 50 % of women are asymptomatic and when symptoms occur, they correlate with the size, location, number and degenerative changes of the fibroid. ⁽⁴⁾ When a STUMP is suspected, conventional surgical treatments are indicated, such as myomectomy or hysterectomy. ⁽²⁾

The objective of this report is to describe a case of recurrent urinary retention secondary to a posterior uterine leiomyoma.

CLINICAL CASE

42-year-old patient, mixed skin color, with a personal pathological history of arterial hypertension treated with enalapril 20 mg daily, anxious-depressive syndrome treated with alprazolam 0.5 mg daily and obstetric history of zero pregnancies. Menarche at age 13, stable partner for more than 15 years. Exfoliative cervical cytology, with Pap stain performed in 2023, without alterations and diagnosis of small uterine myoma between 4-6 cm.

<http://revcimeq.sld.cu/index.php/img>

revinmedquir@infomed.sld.cu

Under Creative Commons license





In September 2022, he began to experience repeated urinary tract infections, for which he received treatment with oral antibiotics. From October of the same year, he presented symptoms of recurrent urinary retention, for which he needed bladder catheterization for three weeks, with periods of up to two weeks without it. He required this procedure on three occasions in the last four months.

She came to the consultation at the beginning of 2023 and, on abdominal examination, a tumor was found in the hypogastrium, painful on deep palpation, 8 cm in diameter above the pubic symphysis. On vaginal examination, the uterus was enlarged, a central tumor slightly deviated to the left was felt, mobile, very painful, with a hard and regular consistency. The right fornix was occupied by an undefined tumor and the parametria were free. On speculscopy, the following were observed: a nabothian cyst on the left side of the cervix, short cervix, wide and elastic vagina. Vital signs on admission: blood pressure: 121/66 mmHg, HR: 77 bpm, respiratory rate: 19 rpm, temperature: 36 ° C, body mass index: 25.25 kg / m2.


Gynecological ultrasound: uterus displaced forward by a lesion with a myomatous appearance located behind it, centrally and which appears to be in close contact with the uterine wall. No appendages are visible. The cervix is displaced to the left.

Computed tomography (CT) with intravenous contrast (Fig. 1): a large tumor mass is observed, located behind the uterus, which it compresses and displaces, as well as the rectus-sigmoid and the bladder, with a density of 35 to 65 Hounsfield units (HU), which increases to 130 HU with the administration of contrast. The bladder is very compressed. The ureters are patent. This lesion presents increased central and peripheral vascularization, which gives the impression of a neoformation.

<http://revcimeq.sld.cu/index.php/img>

revinmedquir@infomed.sld.cu

Under Creative Commons license



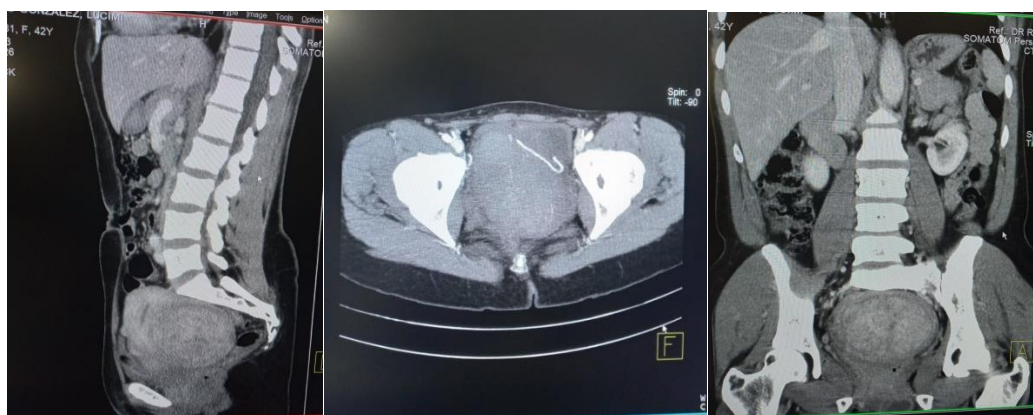


Fig. 1. Abdominal CT scan showing a large posterior uterine tumor compressing the bladder and presenting vessels that appear to be neoformations.

The case was discussed with the medical team and with the patient's consent; it was decided to schedule a total abdominal hysterectomy. During surgery (Fig. 2), a large uterus was observed with a large tumor on the posterior surface. Macroscopically, the adnexa were normal; the right one had adhesions to the uterus. A frozen biopsy was performed, and no malignant characteristics were observed in the sample. The patient had an adequate postoperative evolution and was discharged on the second postoperative day, with the presence of physiological digestive transit and normal urinary function.

The pathological conclusion of the case was: uterus measuring 17 x 13 x 8 cm, with intramural epithelioid leiomyoma measuring 6.5 cm. Cystic follicles, proliferative endometrium and nabothian cysts.

<http://revcimeq.sld.cu/index.php/imq>

revinmedquir@infomed.sld.cu

Under Creative Commons license



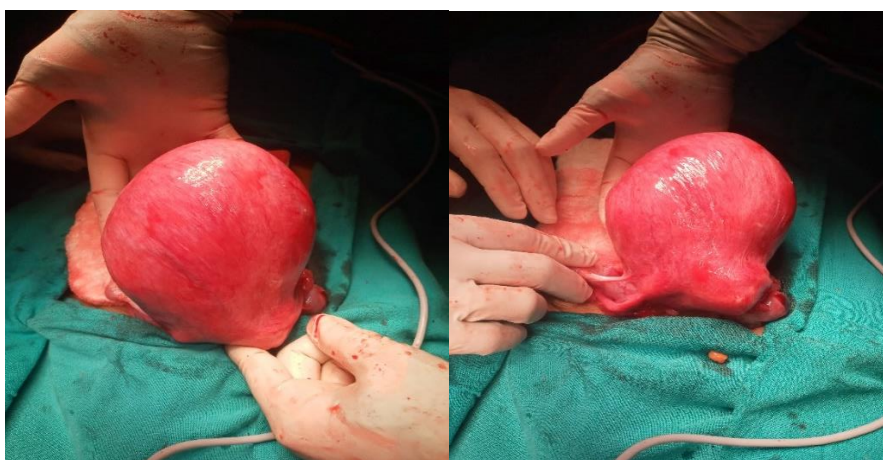

Fig. 2. The uterus is observed during the transoperative period with the presence of a large tumor on the posterior face.

COMMENTS

In the described case, the location of the intramural leiomyoma is reported on the posterior face of the uterine body. The peak of presentation of these tumors is found between the fourth and fifth decades of life; they are exceptional in those under 18 years of age.⁽¹⁾ Their growth tends to regress after menopause, although the risk of developing them in women over 45 years of age is greater than 60 %.⁽¹⁾ Depending on their location in relation to their growth in close proximity to the mucosa or serosa, they are called submucosal or subserous.^(5,6) The symptoms vary from transvaginal bleeding, dysmenorrhea, pelvic pain, constipation and even infertility.

Risk factors include early menarche, nulliparity, and black race. First-degree relatives of patients with myomatosis have a 2.5-fold higher risk of developing it.^(4,5)

In this case, the large abdominal mass and the CT findings suggested that it was a uterine tumor with malignant characteristics. Furthermore, despite its location on the posterior surface of the
<http://revcimeq.sld.cu/index.php/img>
revinmedquir@infomed.sld.cu

Under Creative Commons license





uterine body, the main symptom it caused was urinary retention, which is not the most common symptom in this location.

Uterine leiomyomas are a rare cause of acute urinary retention and only a few case reports and series are documented in the literature. ⁽⁶⁾ Urinary retention frequently occurs in those myomas that grow from the anterior aspect of the cervix and grow in close proximity to the mucosa or serosa. ⁽⁶⁾ The clinical picture includes pollakiuria, bladder tenesmus, urinary retention, polyuria, constipation, dyspareunia and postcoital bleeding. ⁽³⁾

This case highlights the importance of clinical and diagnostic correlation in patients with recurrent urinary retention, as well as the rarity of a posterior leiomyoma that presented with urinary symptoms and imaging signs suspicious for malignancy.

BIBLIOGRAPHIC REFERENCES

1. Singh S, Jena SK, Naik M, Ray L, Behera S. Uterine Fibroid (Leiomyoma) with Acute Urinary Retention: A Case Series. J Clin Diagn Res. 2016; 10 (4): 1-3. DOI: <https://doi.org/10.7860/JCDR/2016/17028.7573>
 2. Mourgues J, Villot A, Thubert T, Fauvet R, Pizzoferrato AC. Uterine myomas and lower urinary tract dysfunctions: A literature review. J Gynecol Obstet Hum Reprod. 2019; 48 (9): 771-774. DOI: <https://doi.org/10.1016/j.jogoh.2019.03.021>
 3. Cotrino I, Carosso A, Macchi C, Baima Poma C, Cosma S, Ribotta M et al. Ultrasound and clinical characteristics of uterine smooth muscle tumors of uncertain malignant potential (STUMPs). Eur J Obstet Gynecol Reprod Biol. 2020; 251: 167-172. DOI: <https://doi.org/10.1016/j.ejogrb.2020.05.040>
- <http://revcimeq.sld.cu/index.php/img>
revinmedquir@infomed.sld.cu

Under Creative Commons license





4. Mohammadi R, Tabrizi R, Hessami K, Ashari H, Nowrouzi-Sohrabi P, Hosseini-Bensenjan M et al. Correlation of low serum vitamin-D with uterine leiomyoma: a systematic review and meta-analysis. *Reprod Biol Endocrinol*. 2020; 18 (1): 85. DOI: <https://doi.org/10.1186/s12958-020-00644-6>
5. Jayes FL, Liu B, Feng L, Aviles-Espinoza N, Leikin S, Leppert PC. Evidence of biomechanical and collagen heterogeneity in uterine fibroids. *Plos One*. 2019; 14 (4): e0215646. DOI: <https://doi.org/10.1371/journal.pone.0215646>
6. Bariani MV, Rangaswamy R, Siblini H, Yang Q, Al-Hendy A, Zota AR. The role of endocrine-disrupting chemicals in uterine fibroid pathogenesis. *Curr Opin Endocrinol Diabetes Obes*. 2020; 27 (6): 380-387. DOI: <https://doi.org/10.1097/MED.0000000000000578>

Conflicts of interest

The authors report no conflicts of interest.

<http://revcimeq.sld.cu/index.php/img>

revinmedquir@infomed.sld.cu

Under Creative Commons license

